

## MASES

Costosternal I re. • li. •

Costosternal VII re. • li. •

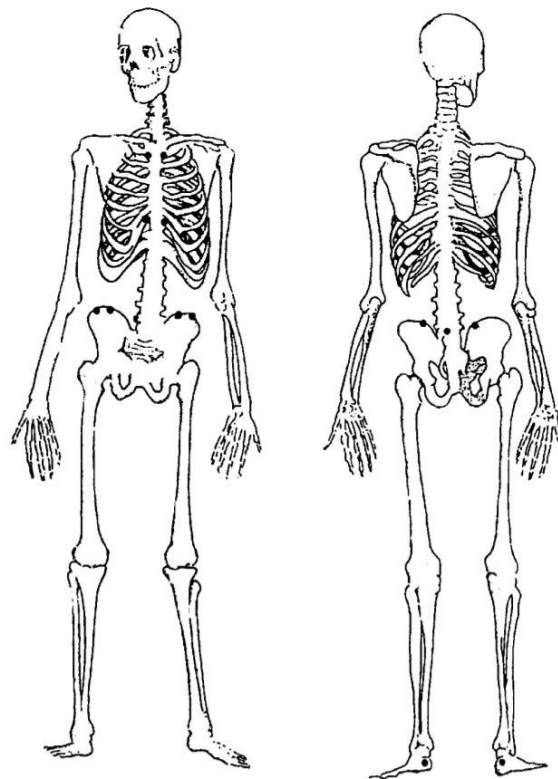
Crista iliaca re. • li. •

Spin. il. ant. sup. re. • li. •

Spin. il. post. sup. re. • li. •

Proc. spin. LWK V •

Achillessehne re. • li. •



MASES: \_\_\_\_\_

Link: <http://www.asas-group.org/publications.php?id=02>

Heuft-Dorenbosch et al. *Ann Rheum Dis* 2003;62:127